

Trunk Inclination, Pelvic Tilt and Pelvic Rotation in Relation to the Craniofacial Morphology in Adults

Carsten Lippold^a; Gholamreza Danesh^a; Gloria Hoppe^b; Burkhard Drerup^c; Lars Hackenberg^d

ABSTRACT

Objective: To relate the differences in the posture of patients with different craniofacial morphologies.

Subjects and Methods: Fifty-three adult patients with Class II and III malformations were examined by cephalometric analysis and rasterstereography. The facial depth, maxillary position, mandibular plane angle, inner gonial angle, facial axis, and lower facial height were evaluated and classified into a basal distal–mesial group and a horizontal-vertical group by means of threshold parameters. Analyzing the results of the rasterstereography, the spine's lateral perpendicular deviation, the pelvic tilt, and the pelvic rotation were calculated by means of mathematical algorithms on the basis of the three-dimensional spine profile. To determine the statistically significant correlations between the studied parameters, the *t*-test was applied in groups with a normal distribution, and the Mann-Whitney *U*-test was used in the cases of abnormally distributed variables (significance level $P < .05$).

Results: Statistically significant differences ($P < .05$) in pelvic torsion were documented with respect to the facial axis and facial depth. Moreover, the differences ($P < .05$) between patients with a skeletal horizontal-vertical facial axis and patients with a basal distal–mesial position for the facial depth could be determined for the pelvic torsion.

Conclusions: As a clinical consequence of the results, an extension of the interdisciplinary concepts within the sense of an orthopedic examination can be considered for patients undergoing a combined orthodontic-operative therapy.

KEY WORDS: Body posture; Craniofacial morphology; Rasterstereography

INTRODUCTION

In international literature, there are indications of correlations between orthodontic and orthopedic findings.^{1–7} Korbmacher et al⁴ summarized these findings in a systematic review. In a study series, the cephalometric assessment of lateral radiographs is used to define the relationship between the head posture and

the cervical inclination.^{1,8–10} Moreover, in some studies the relationship of the length of the lower jaw and the cervical lordosis is described.^{1,11} In this context, Festa et al¹ established a statistically significant correlation between the distal jaw position, the sagittal mandibular length, and an increased cervical lordosis.

D'Attilio et al¹¹ also discovered a statistically significant correlation between the sagittal mandibular position and length, the overjet, and the basic inclination of the lower jaw to the cervical curvature. However, some studies negate the existence of correlations between specific orthopedic findings with certain jaw positions.^{12,13} Michelotti et al⁷ postulated that even though there are descriptions of an interdependence of the upper cervical spine and the jaw position in the literature, there is no evidence of such a relationship in further caudally located spine sections.

For the purpose of diagnosis in orthodontics, lateral radiographs represent a valid examination method for the analysis of parameters such as the sagittal and the vertical jaw positions. By comparison, substantiated

^a Research Scientist, Department of Orthodontics, University of Münster, Münster, Germany.

^b Resident, Department of Orthodontics, University of Münster, Münster, Germany.

^c Professor, Department of Technical Orthopedics, University of Münster, Münster, Germany.

^d Associate Professor, Department of Orthopedics, University of Münster, Münster, Germany.

Corresponding author: Dr Carsten Lippold, Department of Orthodontics, University of Münster, Waldeyerstr 30, Münster, NRW 48129, Germany (e-mail: lippold@uni-muenster.de)

Accepted: January 2006. Submitted: December 2005.

© 2006 by The EH Angle Education and Research Foundation, Inc.

examination methods are rarely used during the orthopedic examination in the presented studies.⁴ Often, a simple subjective clinical orthopedic examination is carried out³⁻⁶ to diagnose forms of bad posture. However, some studies used noninvasive orthopedic measurement methods for the analysis of lordotic or kyphotic angles,¹⁴⁻¹⁸ but no examination technique is described in the orthodontic literature based on light-projection methods and further computerized processing of a three-dimensional back surface profile.

However, apart from the radiographic diagnosis with a specific diagnostic and therapeutic target, it is also possible to carry out a substantiated study of the spine by noninvasive methods (rasterstereography) that have high accuracy and are therefore suitable for studies without subjecting the patient to x-rays.¹⁹⁻²³

The objective of this study was to examine the correlations between parameters of body posture in the frontal profile and the jaw position by using a three-dimensional measurement of the back profile and a cephalometric analysis of the facial skull.

MATERIALS AND METHODS

In the framework of this clinical study, we examined 53 healthy adults (32 women and 21 men; mean age 24.6 years, SD 9.0 years) with skeletal malformations (Class II and III malocclusion) who came to our center for a consultation regarding a combined orthodontic-orthognathic treatment. They revealed no anamnesticly established motor or neurological findings and no previous internal or orthopedic illnesses. All patients were informed of the procedure of the clinical examination and gave their written consent to the study procedure, which was carried out following the criteria of the local Ethics Commission and the Helsinki Criteria. As there was no indication to justifying lateral skull radiographs of a control group, no group of patients with neutral sagittal and vertical skull relation was established.

Cephalometric Analysis

A standardized lateral radiograph (film of 24 × 30 cm, Planex Regular, Kodak, Stuttgart, Germany) of each of the examined patients was taken (focus-film distance 3.2 m; enlargement factor 1%; exposure dates: 15–25 mAs, 72–81 kV). The radiographs were digitalized at a solution of 300 dpi (Scanner: Power Look III, Umax Systems, Willich, Germany). The cephalometric analysis (Figure 1; Table 1) of six angular parameters²⁴ was carried out by means of orthodontic analyzing software (Onyx Ceph Version 2.7.8, Image Instruments, Chemnitz, Germany).

The sagittal position of the maxilla (maxillary position: Ba-N—N-A) and the mandible (facial depth: P-

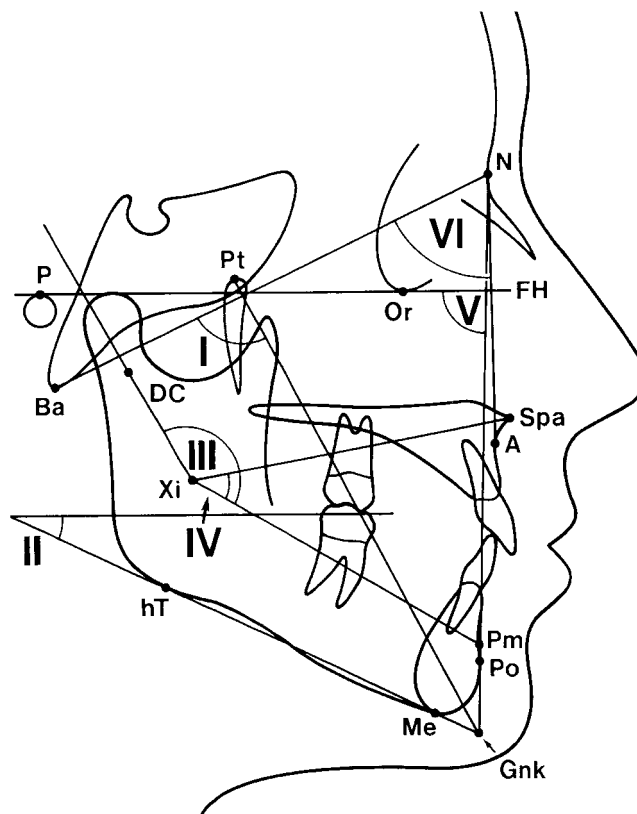


Figure 1. Cephalometric analysis: reference points, lines, and angles (I–VI).

TABLE 1. Cephalometric Analysis: Definition of Reference Points, Lines, and Angles (I–VI)

I	Ba-N-Pt-GnK	Facial axis
II	P-Or-Me-hT	Mandibular plane angle
III	Xi-DC-Xi-Pm	Inner gonial angle
IV	Xi-Spa-Xi-Pm	Lower facial height
V	P-Or-N-Po	Facial depth
VI	Ba-N-N-A	Maxillary position

Or—N—Po) as well as the parameters for the evaluation of the vertical craniofacial morphology—inner gonial angle (Xi-DC—Xi-Pm), facial axis (Ba-N—Pt-GnK), mandibular plane angle (P-Or—Me-hT), and the lower facial height (Xi-Spa—Xi-Pm)—were used for the analysis of the facial skull.

To maintain anonymity for the present study, the patients' names were masked. The method errors in the cephalometric analysis were determined by applying the Dahlberg formula²⁵ (average error ratio (SE²)) = $d^2/2n$, where d is the difference of the measurements at two different times and n is the number of measurements. The measurement was repeated on randomly chosen radiographs by the same examiner after a 2-week interval.

A differentiation of the cephalometric parameters studied with respect to the distal basal-mesial rela-

TABLE 2.

	Statistics									
	Mean	SD	Minimum	Maximum	Lateral Trunk Inclination		Pelvic Tilt		Pelvic Rotation	
					P Value	r ²	P Value	r ²	P Value	r ²
Facial axis	88.6	6.0	71.9	101.0	.156	0.01	.136	0.012	.044*	0.022
Mandibular plane	26.6	7.8	10.6	46.7	.656	0.004	.436	0.018	.228	0.007
Inner gonial angle	147.1	7.7	124.5	164.0	.730	0.004	.490	0.017	.703	0.003
Lower facial height	46.9	7.0	34.0	65.1	1.0	0.002	.941	0.012	.781	0.006
Facial depth	88.2	7.0	75.0	102.3	.156	0.048	.136	0.031	.044*	0.067
Maxilla position	61.4	5.0	52.8	75.0	.924	0.005	.775	0.006	.804	0.008

* Significant; ** highly significant.

TABLE 3.

Cephalometric Measurement Skeletal Pattern	Statistics ^a											
	Facial Axis		Mandibular Plane		Inner Gonial Angle		Lower Facial Height		Facial Depth		Maxilla Position	
	Vertical	Horizontal	Vertical	Horizontal	Vertical	Horizontal	Vertical	Horizontal	Mesial	Distal	Mesial	Distal
	(n = 30)	(n = 23)	(n = 34)	(n = 19)	(n = 21)	(n = 32)	(n = 34)	(n = 19)	(n = 23)	(n = 30)	(n = 17)	(n = 36)
Lateral Trunk inclination, ° (1.79° ± 2.44°)	1.68± 2.62	1.96± 2.23	1.75± 2.30	1.89± 2.30	1.05± 2.04	2.29± 2.58	1.63± 2.47	2.11± 2.42	1.96± 2.23	1.68± 2.62	1.60± 2.51	1.89± 2.51
Pelvic tilt, ° (0.73° ± 3.57°)	1.22± 3.43	0.08± 3.73	1.07± 2.82	0.12± 4.65	1.05± 3.51	0.46± 3.64	-0.13± 3.47	-0.06± 3.95	0.08± 3.43	1.22± 3.43	0.94± 3.33	0.63± 3.72
Pelvic rotation, ° (0.03° ± 3.09°)	-0.57± 2.97	0.82± 3.13	-0.47± 2.53	0.94± 3.80	-0.56± 2.17	0.42± 3.55	-0.12± 2.64	0.31± 3.83	0.82± 3.13	-0.57± 2.97	-0.20± 3.33	0.14± 3.34

^a Given values are mean and standard deviation.

tionship of the maxilla and the mandibular as well as the determination of the vertical craniofacial morphology was achieved. This was done by differentiating the values according to the following thresholds: facial axis, 90°; inner gonial angle, 150°; mandibular plane angle, 23°; lower facial height, 45°; facial depth, 90°; and maxillary position, 64°.

Rasterstereography

In orthopedic diagnostics, rasterstereography^{19,21} (Formetric 2, Diers International GmbH, Schlangenbad, Germany) carried out in the framework of the clinical monitoring and the postoperative follow-up after scoliosis surgery is an established examination method.^{22,23} It permits a three-dimensional representation of the dorsal profile and is based on the methods of photometry.

For this procedure, a projection unit emits a white light grid onto the dorsal surface of the patient standing in a defined way toward the projection device, which then obtains measuring data on the dorsal profile by means of a video-optic device from another direction.²⁶ Rasterstereography excels by its high precision (methodic error <0.1 mm) and allows a radiation-free representation of the profile. For angular

data, the reproducibility of an individual rasterstereographic shot is indicated with 2.8°.²⁷ The measuring speed of 0.04 seconds can be considered as quick, and the total dorsal surface is registered simultaneously. An automatic recognition of anatomical structures (vertebra prominens [VP], spina iliaca [SI], right crista iliaca posterior superior [DR], and left crista iliaca posterior superior [DL]) by means of the connected software provides the basis for a reconstruction of the three-dimensional profile of the dorsal surface.²⁸ Figure 2 shows a typical three-dimensional profile. By means of mathematical algorithms, a two-dimensional median sagittal or frontal-posterior dorsal profile is generated.

As an examination parameter, the lateral trunk inclination (mm/°) was studied as an angle between the vertical based on the VP and the straight line between VP and the center point of the straight line between the DR and the DL (Figure 3a). Positive values defined a perpendicular deviation to the left and a negative deviation to the right.

For the pelvic tilt, the difference in height between the DR and the DL was measured in millimeters (Figure 3b). The angle between the vertical passing through DR and DL to the horizontal reference plane was defined as angular measure in degrees.

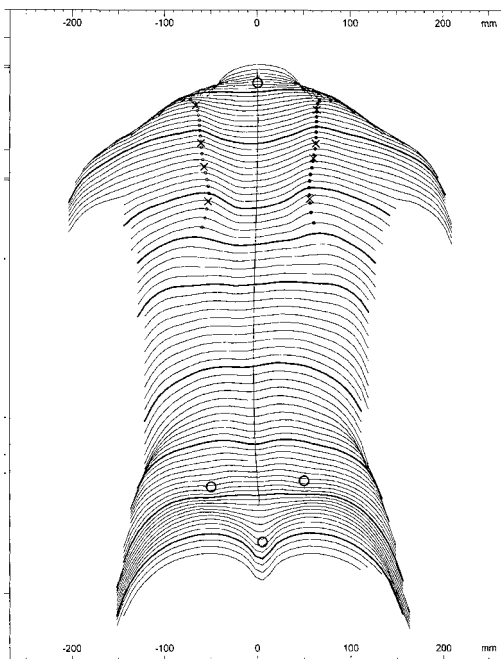


Figure 2. A rasterstereographic surface reconstruction of the back profile of a patient in this study: transverse profiles and symmetry lines.

Pelvic torsion was measured by the angle between the surface normals to the lumbar dimples indicating the SI posterior superior landmark (Figure 3c). In a symmetric pelvis without torsion of the iliac bones, pelvic torsion angle is 0° . The angle is positive if the surface normal to the right dimple points lower than the surface normal to the left dimple, indicating the DR to be rotated backward whereas the DL is rotated forward.

Statistics

SPSS 12.0 (Lead Tech, Chicago, Ill) served for the statistical analysis of the determined measurements. For the descriptive statistics, the mean values with standard deviations were indicated as well as the minimum and the maximum. The Pearson test was used for the calculation of correlations. In the range diagram, r^2 was calculated for further differentiation of the direction of the linear dependence. For further differentiation of the examined cephalometric parameters into horizontal-vertical and basal distal-mesial skeletal facial patterns, the following border levels were determined: facial axis, 90° ; inner gonial angle, 150° ; mandibular plane angle, 23° ; lower facial height, 45° ; facial depth, 90° ; and maxillary position, 64° . To determine the statistically significant differences between the groups, the *t*-test was applied to normally distributed groups, and the Mann-Whitney *U*-test was applied to

abnormally distributed variables. In all tests the significance level was determined to be $P < .05$.

RESULTS

The standard error in the evaluation of the lateral radiographs for the analysis of the angular measures was lower than 0.5° . This value was applied in reference to Trpkova et al.²⁹ The results of the cephalometric and rasterstereographic analysis are summarized in Tables 2 and 3.

For the cephalometric analysis of the lateral radiographs, the mean value determined was 88.6° for the facial axis (I) (SD 6.0° ; min 71.9° , max 101.0°), 26.6° for the mandibular plane angle (II) (SD 7.8° ; min 10.6° , max 46.7°), 147.1° for the inner gonial angle (III) (SD 7.7° ; min 124.5° , max 164.0°), 46.9° for the lower facial height (IV) (SD 6.9° ; min 34.0° , max 65.1°), 88.2° for the facial depth (V) (SD 7.0° ; min 75.0° , max 102.3°), and 61.4° for the maxillary position (VI) (SD 5.0° ; min 52.8° , max 75.0°).

The evaluation of the lateral trunk inclination toward the vertical revealed a mean value of 1.79° (SD 2.4° ; min 3.01° , max 6.79°). There was no statistically significant difference ($P > .05$) to the cephalometric parameters. No statistically significant differences were found between the groups in the individual cephalometric angles (horizontal-vertical and basal distal-mesial).

The mean value of the pelvic tilt amounted to 0.72° (SD 3.57° ; min 10.41° , max 8.03°). Moreover, there were no statistically significant differences ($P > .05$) with the cephalometric parameters.

On average, the pelvic torsion amounted to 0.03° (SD 3.09° ; min 6.42° , max 13.32°), which is in excellent agreement with the expectation of a symmetric pelvis with pelvic torsion 0° . No correlation to cephalometric measurements could be determined with the Pearson test. However, statistically significant differences ($P < .05$) were documented regarding the facial axis and the facial depth between horizontal-vertical or basal distal-mesial groups. Patients with a vertical value on the facial axis and a skeletal distal value in the facial depth had on average 0.57° (SD 3.12°), indicating a slight pelvic torsion where the DL is rotated backward with respect to the DR, and patients with a horizontal and mesial relation revealed an average of 0.81° (SD 2.97°), showing a slight rotation of the DR rotated backward regarding the contralateral side.

DISCUSSION

The wide range of cephalometric values of the lateral radiographs is the result of the specific patient group. The group members are allocations for the implementation of orthodontic-operative combination

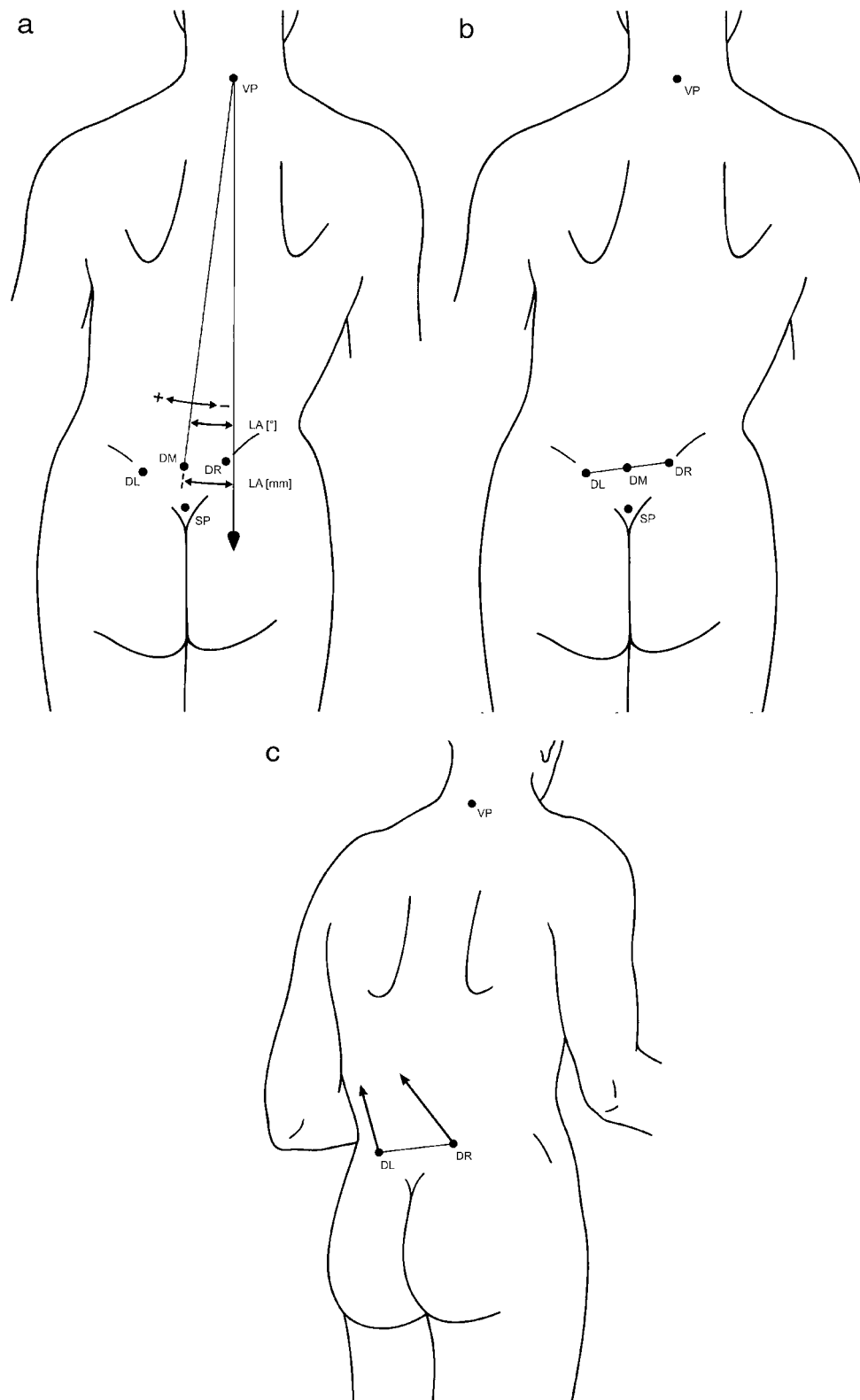


Figure 3. (a) Lateral trunk inclination (LA [mm²]): an angle between the vertical based on the vertebra prominens (VP) and the straight line between VP and the center point of the straight line between the right crista iliaca posterior superior (DR) and the left crista iliaca posterior superior (DL). (b) Pelvic tilt: the difference in height between the DR and the DL measured in millimeters. The angle between the vertical passing through DR and DL to the horizontal reference plane was defined as angular measure in degrees. (c) Pelvic torsion was measured by the angle between the surface normals to the lumbar dimples indicating the spina iliaca posterior superior landmark. In a symmetric pelvis without torsion of the iliac bones, pelvic torsion angle is 0°. The angle is positive if the normal to the right dimple points lower than the normal to the left dimple, indicating the DR to be rotated backward whereas the DL is rotated forward.

treatments that are indicated only in the case of distinctive forms of dysgnathia. Hence, for this study, patients with angle Class II and III as well as vertical forms of dysgnathia were examined. The dental parameters were not taken into consideration, as they do not say anything about the intensity of the skeletal deformity attributed to natural compensation.

The present study is based on exact cephalometric values for the analysis of the position of the jaw in which a slight methodological error could be proven. An examination using objective methods with the aim to analyze the body posture would have been possible by means of radiographs of the thorax.³⁰ However, in view of the radiation exposure of the patients, it would not have been justifiable to use such an approach for a clinical study. Regarding the relationship of the cervical spine and the jaw position, there are several studies describing the jaw position and the spine inclination on the basis of the analysis of lateral radiographs.^{8–10,12,13,31,32} Here, the literature's postulation regarding the use of the upper spine section to substantiated examination procedures for the valid verification of the body posture has been fulfilled.^{4,7}

As already mentioned by Korbmacher et al,⁴ there are no studies on the relationship of the jaw position to the body posture regarding spine sections below the cervical spine that use substantiated study procedures. Our own previous studies also had this deficiency in the analysis of the body posture,^{5,6} and this deficiency was meant to be eliminated with the rasterstereography used in the present spine examination study. Until now, an orthopedic clinical examination has been used for orthopedic diagnostics, but today we are able to use a quick, cost-effective, and valid examination method to assess the body posture.

The high accuracy of this method used on scoliosis patients was clinically confirmed by Drerup et al²⁰ and compared with customary thorax radiographs by Hackenberg et al.^{22,23} In this way it is possible to carry out an assessment of the body posture of a patient with skeletal dysgnathia in cooperation with the department of orthopedics. In the general orthodontic practice, an interdisciplinary cooperation with orthopedic consultants would be possible if they were familiar with rasterstereography.

In the statistical analysis, a significant difference concerning the pelvic torsion was observed between patients with a horizontal-vertical angle of the facial axis and patients with a basal distal–mesial facial depth. No statistically significant correlations could be found in cephalometric parameters where the maxilla played a role. Thus, the mandible seems to be more closely related to a possible pelvic torsion. Although these angles give no indication on a facial asymmetry, this correlation indicates that a thorough analysis of

facial asymmetry in correlation with trunk asymmetry is necessary and may reveal important interrelations in skeletal shape.³¹ Therefore, posteroanterior radiographs for determining facial asymmetry could be used in future studies.

The close anatomical and neuronal (sensory and motor) linkage between the upper cervical spine and the craniofacial section documented in literature accounts for relationships between the jaw position and the inclination of the cervical spine.^{4–6,8–10,12,15,18,32,33} The results of the present study contradict the statements made by Michelotti et al,⁷ who could furnish evidence for the correlations between the jaw position and the body posture but not for lower spine sections.

The noninvasive method of examination of the body posture offers the possibility to analyze the prospective development of the jaw position and the body posture of children and youths with the possible influence of an orthodontic therapy included in the treatment objectives.

CONCLUSIONS

- Correlations between the pelvic torsion and the facial axis as well as the pelvic torsion and the facial depth indicate possible relationships between the vertical and the sagittal position of the lower jaw and the body posture.
- As a clinical consequence of our own results, an extension of the interdisciplinary concept in the sense of an orthopedic examination by means of rasterstereography could be taken into consideration for patients with a combined orthodontic-orthognathic surgery treatment.

REFERENCES

1. Festa F, Tecco S, Dolci M, Ciufolo F, Di Meo S, Filippi MR, Ferritto AL, DAtillio M. Relationship between cervical lordosis and facial morphology in Caucasian women with skeletal Class II malocclusion: a cross sectional study. *Cranio*. 2003;21:121–129.
2. Gresham H, Smithells PA. Cervical and mandibular posture. *Dent Rec*. 1954;74:261–264.
3. Hirschfelder U, Hirschfelder H. Sagittale Kieferrelation und Wirbelsäulenhaltung: Untersuchungen zur Frage einer Abhängigkeit. *Fortschr Kieferorthop*. 1987;48:436–448.
4. Korbmacher H, Eggers-Stroeder G, Koch L, Kahl-Nieke B. Correlations between anomalies of the dentition and pathologies of the locomotor system—a literature review. *J Orofac Orthop*. 2004;65:190–203.
5. Lippold C, van den Bos L, Ehmer U. Beziehungen zwischen kieferorthopädischen und orthopädischen Befunden. *Man Med*. 2000;38:346–350.
6. Lippold C, van den Bos L, Hohoff A, Danesh G, Ehmer U. Interdisciplinary study of orthopedic and orthodontic findings in pre-school infants. *J Orofac Orthop*. 2003;64:330–340.
7. Michelotti A, Manzo P, Farella M, Martina R. Occlusion and posture: is there evidence of correlation? *Minerva Stomatol*. 1999;48:525–534.

8. Huggare JAV, Cooke MS. Head posture and cervicovertebral anatomy as mandibular growth predictors. *Eur J Orthod.* 1994;16:175–180.
9. Nobili A, Adversi R. Relationship between posture and occlusion: a clinical and experimental investigation. *Cranio.* 1996;14:274–285.
10. Solow B, Sandham A. Cranio-cervical posture: a factor in the development and function of the dentofacial structures. *Eur J Orthod.* 2002;24:447–456.
11. D'Attilio M, Epifania E, Ciuffolo F, Salini V, Filippi MR, Dolci M, Festa F, Tecco S. Cervical lordosis angle measured on lateral cephalograms; findings in skeletal Class II female subjects with and without TMD: a cross sectional study. *Cranio.* 2004;22:27–44.
12. Solow B, Tallgren A. Dentoalveolar morphology in relation to craniocervical posture. *Angle Orthod.* 1977;47:157–164.
13. Sterzik G, Graßhoff H, Lentschow B. Morphologische Verknüpfungen von Euginathien, Gebißanomalien der Klasse II/1 und Klasse III mit Veränderungen der Topographie der Halswirbelsäule im Fernröntgenseitenbild. *Fortschr Kieferorthop.* 1992;53:69–76.
14. Debrunner HU. The Kyphometer. *Z Orthop Ihre Grenzgeb.* 1972;110:389–392.
15. Helling E, McWilliam J, Reigo T, Spangfort E. The relationship between craniofacial morphology, head posture and spinal curvature in 8, 11 and 15-year-old children. *Eur J Orthod.* 1987;9:254–264.
16. Willner S. Spinal pantograph—a non-invasive technique for describing kyphosis and lordosis in the thoraco-lumbar spine. *Acta Orthop Scand.* 1981;52:525–529.
17. Vercauteren M, Van Beneden M, Verplaetse R, Croene P, Uyttendaele D, Verdonk R. Trunk asymmetries in a Belgian school population. *Spine.* 1982;7:555–562.
18. Zepa I, Hurmerinta K, Kovero O, Nissinen M, Kononen M, Huggare J. Trunk asymmetry and facial symmetry in young adults. *Acta Odontol Scand.* 2003;6:149–153.
19. Drerup B, Hierholzer E. Back shape measurement using video rasterstereography and three-dimensional reconstruction of spinal shape. *Clin Biomech.* 1994;9:28–36.
20. Drerup B, Hierholzer E, Ellger B. Shape analysis of the lateral and frontal projection of spine curves assessed from rasterstereographs. In: Sevastik JA, Diab KM, eds. *Research Into Spinal Deformities.* 1st ed. Amsterdam, The Netherlands: IOS Press; 1997:271–275.
21. Frobin W, Hierholzer E. Rasterstereography: a photogrammetric method for measurement of body surfaces. *Photogrammetric Eng Remote Sensing.* 1981;47:1717–1724.
22. Hackenberg L, Hierholzer E, Potzl W, Gotze C, Liljenqvist U. Rasterstereographic back shape analysis in idiopathic scoliosis after posterior correction and fusion. *Clin Biomech.* 2003;18:883–889.
23. Hackenberg L, Hierholzer E, Pötzl W, Götze C, Liljenqvist U. Rasterstereographic back shape analysis in idiopathic scoliosis after anterior correction and fusion. *Clin Biomech.* 2003;18:1–8.
24. Proffit WR. *Contemporary Orthodontics.* 3rd ed. St Louis, Mo: CV Mosby Co; 2000.
25. Dahlberg A. *Statistical Methods for Medical and Biological Students.* New York, NY: Interscience Publications; 1940.
26. Hierholzer E, Drerup B. High-resolution rasterstereography. In: D'Amico M, Merolli A, Santambrogio GC, eds. *Three-Dimensional Analysis of Spinal Deformities.* Amsterdam, The Netherlands: IOS Press; 1995:435–439.
27. Drerup B. The measurement of the kyphotic angle by contact free registration of back-shape. *Z Orthop Ihre Grenzgeb.* 1982;120:64–70.
28. Drerup B, Hierholzer E. Automatic localization of anatomical landmarks on the back surface and construction of a body-fixed coordinate system. *J Biomech.* 1987;20:961–970.
29. Trpkova B, Major P, Prasad N, Nebbe B. Cephalometric landmarks identification and reproducibility: a meta analysis. *Am J Orthod Dentofacial Orthop.* 1997;112:165–170.
30. Vialle R, Levassor N, Rillardon L, Templier A, Skalli W, Guigui P. Radiographic analysis of the sagittal alignment and balance of the spine in asymptomatic subjects. *J Bone Joint Surg Am.* 2005;87:260–267.
31. Goldberg CJ, Dowling FE. Idiopathic scoliosis and asymmetry of form and function. *Spine.* 1991;16:84–87.
32. Huggare JAV. The first cervical vertebra as an indicator of mandibular growth. *Eur J Orthod.* 1989;11:10–16.
33. Solow B, Siersback-Nielsen S. Cervical and craniocervical posture as predictors of craniofacial growth. *Am J Orthod Dentofacial Orthop.* 1992;101:449–458.